



Treatment of locally advanced and metastatic basosquamous carcinoma, navigating among sonic hedgehog pathway inhibitors, immune checkpoint inhibitors, chemotherapy, and radiotherapy: A case series and literature review

Enrico Zelin MD¹ | Vanessa Mazzoletti MD² | Francesco Cavallo MD³ |
 Carlotta Nardello MD¹ | Andrea Corio MD¹ | Ludovica Toffoli MD¹ |
 Luca Tagliaferri MD, PhD⁴ | Claudio Conforti MD^{1,5} | Nicola Di Meo MD¹ |
 Iris Zalaudek MD¹

¹Dermatology Clinic, Maggiore Hospital, University of Trieste, Trieste, Italy

²Department of Health Science, University of Eastern Piedmont, Novara, Italy

³Section of Dermatology, Department of Medical Sciences, University of Turin, Turin, Italy

⁴UOC Radioterapia Oncologica, Dipartimento di Diagnostica per Immagini, Radioterapia Oncologica ed Ematologia, Fondazione Policlinico Universitario A, Gemelli IRCCS, Rome, Italy

⁵Dermatological Research Hospital, IDI IRCCS, Rome, Italy

Correspondence

Enrico Zelin, Dermatology Clinic, Maggiore Hospital, Piazza dell'Ospitale 1, Trieste 34129, Italy.

Email: enrico.zelin@gmail.com

Abstract

Locally advanced (laBSCs) and metastatic basosquamous carcinomas (mBSCs) represent a therapeutic challenge. By definition, these forms are not amenable to surgery or radiotherapy, but according to literature reports, sonic hedgehog pathway inhibitors (HHIs), anti-programmed death 1 receptor antibodies (anti-PD-1), and other treatment approaches involving chemotherapy, surgery, and radiotherapy have been used. This work features 5 real-life cases of advanced BSCs, treated at the Dermato-Oncology Unit of Trieste (Maggiore Hospital, University of Trieste). In addition, a review of the current treatment options reported in the literature for laBSC and mBSC is provided, collecting a total of 17 patients. According to these preliminary data, HHIs such as sonidegib and vismodegib could represent a safe and effective first line of treatment, while the anti-PD-1 cemiplimab may be useful as a second-line option. Chemotherapy and combined approaches involving surgery and radiotherapy have been also reported to be suitable in some patients.

KEYWORDS

cemiplimab, chemotherapy, locally advanced basosquamous carcinoma, metastatic basosquamous carcinoma, nivolumab, radiotherapy, review, sonic hedgehog pathway inhibitors, sonidegib, surgery, treatment, vismodegib

This is an open access article under the terms of the [Creative Commons Attribution](https://creativecommons.org/licenses/by/4.0/) License, which permits use, distribution and reproduction in any medium, provided the original work is properly cited.

© 2023 The Authors. *Australasian Journal of Dermatology* published by John Wiley & Sons Australia, Ltd on behalf of Australasian College of Dermatologists.



INTRODUCTION

Cutaneous basosquamous carcinoma (BSC) is a rare variant of basal cell carcinoma with areas of squamous differentiation, characterized by aggressive local growth and metastatic potential. Locally advanced BSC (laBSC) is defined as a BSC not amenable to surgery or radiotherapy.¹

To date, no standard therapy for laBSC or metastatic BSC (mBSC) has been established, although many treatment possibilities have been described, including sonic hedgehog pathway inhibitors (HHIs), immune checkpoint inhibitors (ICIs) as anti-programmed death 1 (anti-PD-1) receptor antibodies, chemotherapy, and combined approaches involving surgery and radiotherapy (RT).^{2,3}

This work provides a review of the treatment options reported in the literature for laBSC and mBSC, together with the description of 5 real-life cases of advanced BSCs, treated at Dermato-Oncology Unit of Trieste (Maggiore Hospital, University of Trieste).

METHODS

For this review, a search of PubMed, [Science.gov](#), and [ClinicalTrials.gov](#) databases has been performed, using the keywords 'locally advanced basosquamous carcinoma', 'metastatic basosquamous carcinoma' in combination with 'sonic hedgehog pathway inhibitors', 'sonidegib', 'vismodegib', 'immunotherapy', 'anti-PD-1', 'cempilimab', 'nivolumab', 'chemotherapy', 'radiotherapy'. Only articles in English were selected. Other potentially relevant articles were identified by manually checking the references of the included literature.

RESULTS

Sonic HHIs

Sonidegib and vismodegib are sonic HHIs, whose efficacy is well documented in the treatment of locally advanced basal cell carcinoma (laBCC) and metastatic basal cell carcinoma (mBCC), although sonidegib is not approved for mBCC.¹ Their role in laBSC and mBSC was at first controversial, because of the potential association between HHIs use and increased risk of squamous cell carcinomas (SCCs) development. Specifically, new-onset SCCs⁴ appearance and squamous transformation of BCCs during vismodegib therapy have been reported,^{5,6} but other studies (a retrospective cohort study and a narrative review) have not confirmed these data.^{7,8}

As far as concerns sonidegib, only a few reports have been published (probably due to the quite recent approval of this drug), limited to the laBSC setting. In a 63-year-old man with 2 large BSCs of the face, sonidegib associated with itraconazole was given as third-line therapy, after vismodegib and anti-PD-1 failure, with good response, maintained for 10 months.⁹ However, a case of sonidegib failure in laBSC treatment was also reported in the literature: in a 60-year-old man with a giant BSC of the midface, no response to sonidegib after 9 months and increasing adverse events led to therapy discontinuation.¹⁰ Among the patients treated at the Dermato-Oncology Unit of Trieste, sonidegib was effective, with a partial response (PR) after 3–6 months in 4 patients with laBSC (Patient A-D, [Table 1](#), [Supplementary Material 1](#)), although this outcome was not maintained in patients A and B. Of note, patients A-C ([Figures 1 and 2](#)) have been formerly described by Toffoli et al. in previous works.^{2,3}

As far as concerns vismodegib, many reports have documented encouraging results about its use in laBSCs and mBSCs. Apalla et al. described an excellent outcome in 2 elderly patients (78- and 87-year-old women) affected by laBSCs. In both cases, tumours were located on the nose and complete response (CR) was obtained after 6 months of vismodegib therapy. Moreover, no recurrence was documented 18 and 12 months after therapy discontinuation, respectively.¹³ A similar outcome with vismodegib was reported in a 45-year-old female patient with a laBSC of the face: a CR was observed after 7 months and no evidence of recurrence was documented 9 months after treatment discontinuation.¹⁴ Vismodegib effectiveness has also been shown in metastatic patients. McGrane et al. reported its use in a 66-year-old patient with a BSC located in the chest wall with nodal, lung and vertebral metastasis. Twenty-eight months after therapy initiation, a minimal nodular regrowth on the primary tumour site was detectable, whereas a stable metastatic disease was maintained.¹⁵

Despite this positive evidence indicating that vismodegib is highly effective in BSCs, some works documented the opposite scenario. In a 61-year-old woman with a laBSC of the left shoulder and axilla infiltrating chest muscles and bones, previously treated with surgery and RT, vismodegib had to be discontinued because of intolerable side effects.¹⁷ In addition, vismodegib turned out to be a failure in an 82-year-old male patient affected by a mBSC of the face with nodal and bone involvement: disease progression was observed at PET-TC 3 months after starting therapy.¹¹ Among the patients treated at the Dermato-Oncology Unit of Trieste, Patient E ([Figure 3](#)) was treated with vismodegib for 2 months with slight improvement, but the treatment was precociously discontinued after an ischemic stroke ([Table 1](#) and [Supplementary Material 1](#)).



Immune checkpoint inhibitors

Immune checkpoint inhibitors (ICIs) are monoclonal antibodies directed against immunologic receptors on the surface of T-lymphocytes, whose main role is to boost anti-cancer immune response. The discovery of ICIs has revolutionized the treatment landscape of different cancers. Cemiplimab, pembrolizumab and nivolumab are ICIs that target programmed-cell death receptor 1 (PD-1) and their main usage is in SCC and melanoma therapies.²⁰ Cemiplimab is currently approved for locally advanced and metastatic SCC not amenable to curative surgery or curative radiation. Moreover, cemiplimab has been recently approved in Europe for laBCC and mBCC, as an effective second-line option for those who fail or cannot tolerate HHIs.²¹ Pembrolizumab is approved for the treatment of locally advanced and metastatic SCC only in the US, but not in Europe. Finally, nivolumab has not yet an approval for advanced or metastatic non-melanoma skin cancer, and its usage in this setting is limited to phase II studies.^{22,23}

Given the evidence that ICIs are effective drugs in both SCC and BCC, they have been used in BSC too; however, there are only a few ICIs-treated BSCs cases reported in the literature.^{3,24}

Cemiplimab in BSC is typically employed as a second-line therapy after development of secondary resistance to HHIs. Its use has been documented in a 63-year-old man with two laBSCs of the face, after ineffective vismodegib treatment.⁹ However, after five anti-PD-1 infusions, imaging revealed disease progression, leading to cemiplimab discontinuation.⁹ Conversely, Gambichler et al. reported cemiplimab effectiveness in a 60-year-old man with a giant BSC of the midface, after an unsuccessful 9-month treatment with sonidegib, burdened by increasing HHI adverse effects. After 6 cycles of cemiplimab, a CR was achieved without residual BSC detectable at histopathology. The treatment was continuing without adverse events at the time of the publication.¹⁰ In one of the patients treated at the Dermato-Oncology Unit of Trieste (Patient A, [Figure 1](#)), cemiplimab was used after sonidegib failure for a laBSC and this treatment appeared to be synergistic to radiotherapy ([Table 1](#) and [Supplementary Material 1](#)).

If the experience with cemiplimab in advanced BSC is limited, nivolumab use is even less consistent. Indeed, the role of nivolumab in advanced BSC has been mentioned in the literature in a single case: Borradori et al. reported its use in a 61-year-old woman with laBSC and mBSC. The primary lesion, located in the left shoulder and axilla, had been previously treated with surgery, RT, vismodegib and a chemotherapy combination

(carboplatin plus paclitaxel), but the patient had subsequently developed metastatic lung nodules. However, after four nivolumab infusions a PR was detected, with the stabilization of three lesions and a decrease in size of one of the metastatic nodules. Unfortunately, the treatment could not continue due to the patient's death from acute bacterial pneumonia.¹⁷

Chemotherapy

As far as concerns chemotherapy (CT) for laBSC and mBSC, there is no currently approved regimen. According to the literature, advanced BSCs were treated with a combination of paclitaxel and carboplatin^{11,17} and intraarterial cisplatin (10mg weekly for each carotid for 4 months, 400mg in total).¹² In general, CT was used after HHIs therapy, with the exception of one case (CT was preferred to vismodegib because the HHI was not reimbursed).¹² CT was well tolerated and allowed to obtain CR in 2 patients (follow-up data lacking).

Radiotherapy

Treatment with radiotherapy (RT) either alone or in combination with surgery could be one of the primary approaches for BSC management if standard surgical excision is not possible anymore or could result in not optimal aesthetic outcomes.²⁵ As a matter of fact, many patients have history of previous surgery and RT that precede a recurrence ([Table 1](#)), but laBSCs and mBSC, by definition, are not amenable to surgery or RT. However, in this context, RT can be sometimes combined with surgery as post-operative treatment in the scenario of positive margins^{16,18} or in a palliative setting.¹⁹ RT can also be associated with medical treatment, especially cemiplimab, such as in one of the patients treated at the Dermato-Oncology Unit of Trieste (Patient A, [Figure 1](#)), in order to improve response ([Table 1](#) and [Supplementary Material 1](#)). There is evidence that RT could improve ICIs immunotherapy by creating a more immunogenic tumoral environment with release of antigens and neoantigens, triggered by cell damage and apoptosis.²⁶

When planning RT, several host and tumour factors must be taken into consideration: patient's general conditions (performance status) and specific comorbidities that might prevent withstanding of the treatment, the possibility of delivering curative doses of radiation without damaging vital structures, the locoregional volumetric extension of the disease, the presence or absence of distant metastases.¹⁹



TABLE 1 Clinical features, therapy, tumour responses and adverse events in patients with locally advanced or metastatic basosquamous carcinoma.

Author, year				
Or case series patient	Age (years); sex	Localization (size, if present)	N (nodal metastasis); M (distant metastasis)	Treatment (duration); response
Papageorgiou et al. ¹¹	82; M	Face with bone involvement	N yes (right anterior neck); M no	<ul style="list-style-type: none"> 1L: vismodegib (3 months); PD 2L: carboplatin + paclitaxel CT (3 months); CR
Gambichler et al. ¹⁰	60; M	Midface	N no; M no	<ul style="list-style-type: none"> 1L: sonidegib (9 months); no response 2L: cemiplimab (6 cycles); CR
Ramelyte et al. ⁹	63; M	Face, left frontotemporal region	N no; M no	<ul style="list-style-type: none"> 1L: vismodegib (6 months): PR Break for 1 year 2L: cemiplimab (5 cycles): clinical response but progression at imaging 3L: sonidegib + itraconazole (10 months); PR, but development of a subcutaneous nodule (excised)
Sheen et al. ¹²	90; F	Midface (6 × 5 cm)	N no; M no	<ul style="list-style-type: none"> 1L: intraarterial cisplatin CT (weekly infusion for 4 months, 400 mg in total); “dramatic regression of the tumour”
Apalla et al. ¹³	78; F	Nose	N no; M no	<ul style="list-style-type: none"> 1L: vismodegib (6 months), CR
	87; F	Nose	N no; M no	<ul style="list-style-type: none"> 1L: vismodegib (6 months), CR
Sahuquillo-Torralba et al. ¹⁴	45; F	Frontal area with bone involvement (13 cm)	N no; M no	<ul style="list-style-type: none"> 1L: vismodegib (7 months), CR
McGrane et al. ¹⁵	66; M	Right chest wall	N yes (axillary); M yes (lung and T8 vertebra metastasis)	<ul style="list-style-type: none"> 1L: surgical decompression + vismodegib (28 months); marked improvement of cutaneous disease and stable metastatic disease
Bisgaard et al. ¹⁶	86; F	Right shoulder (6 × 7.5 cm)	N no; M no	<ul style="list-style-type: none"> 1L: surgery with positive deep margin + RT; no clinical evidence of disease
Borradori et al. ¹⁷	61; F	Left shoulder and axilla	N no; M yes (lung metastases)	<ul style="list-style-type: none"> 1L: vismodegib 2L: carboplatin + paclitaxel CT and amputation of the arm 3L: nivolumab (5 cycles, 3 mg/kg every 2 weeks); SD
Al-Wassia et al. ¹⁸	54; M	Center of the face	N no; M no	<ul style="list-style-type: none"> 1L: surgery + RT (70 Gy, 35 fractions over 7 weeks); shrinkage of the tumour after 12 months
Deganello et al. ¹⁹	54; M	Frontal area (3 × 2 cm) and left parotid area (10 × 5 cm)	N yes (left parotidean-cervical region); M no	<ul style="list-style-type: none"> 1L: surgery + RT (44 Gy); tumour reduction



Last follow-up	Additional information	Adverse events (if reported)
–	Primary tumour was defined as BCC NOS; N as BSC	–
Continuing cemiplimab (time of publication)	Patient refused first-line RT	Sonidegib: weight loss and alopecia
–	Itraconazole dosage: 100 mg/day, 2 weeks on and 2 weeks off	Vismodegib: weight loss
–	–	Cisplatin: mild anorexia and malaise
Free of recurrence 18 months after cessation of therapy	Previous repetitive surgery and RT	–
Free of recurrence 12 months after cessation of therapy	Previous repetitive surgery and RT	–
Free of recurrence 9 months after cessation of therapy	–	Vismodegib: alopecia, dysgeusia, and muscle spasms (after 4 months)
Continuing vismodegib (time of publication)	–	Vismodegib: fatigue and intermittent muscle spasms in the legs
–	–	–
Deceased 5,5 months after initiation of nivolumab (bacterial pneumonia, ileus)	Previous surgery and RT	Vismodegib: intolerable adverse effects (NOS); nivolumab: grade II hepatitis (liver transplanted patient), fatigue
–	Previous surgery	Dry eye and mouth
Disease stable after 18 months of follow-up	The patient refused adjuvant CT after RT	–



TABLE (Continued)

Author, year				
Or case series patient	Age (years); sex	Localization (size, if present)	N (nodal metastasis); M (distant metastasis)	Treatment (duration); response
Patient A (Figure 1)	59; F	Left upper limb (10 × 15 cm) with muscle infiltration	N no; M no	<ul style="list-style-type: none"> • 1L: sonidegib (8 months); initial PR after 6 months; then PD • 2L: cemiplimab (6 cycles); SD • 3L: RT (55 Gy, 22 fractions)+ cemiplimab (6 cycles); good response • Final treatment: radical excision
Patient B	78; M	Left frontal region (4 cm) with orbital invasion	N no; M no	<ul style="list-style-type: none"> • 1L: sonidegib (9 months, 200 mg on alternated days after the first 3 months); initial PR after 3 months; then PD
Patient C (Figure 2)	83; F	Left shoulder (15 cm)	N no; M no	<ul style="list-style-type: none"> • 1L: sonidegib (4 months, last month 200 mg on alternated days), almost CR • Lost at follow-up for 8 months; relapse • 2L: rechallenge with sonidegib (5 months, first 2 months 200 mg on alternated days); PR
Patient D	78; F	Left frontal region and glabella (5 cm) with orbital invasion	N no; M no	<ul style="list-style-type: none"> • 1L: sonidegib (7 months, 200 mg on alternated days with 2 weeks discontinuation periods after the first 3 months); PR
Patient E (Figure 3)	75; F	Lumbar region (20 cm)	N yes (right inguinal); M uncertain (lung nodule, non-specific histology)	<ul style="list-style-type: none"> • 1L: vismodegib (2 months); slight improvement

Note: If not otherwise specified, treatment regimens were: sonidegib 200 mg/day; vismodegib 150 mg/day; cemiplimab 350 mg every 3 weeks. The cohort is based on literature data and a case series of patients treated at the Dermato-Oncology Unit of Trieste, Maggiore Hospital, University of Trieste [patients A-E]. Abbreviations: 1L, first line; 2L, second line; 3L, third line; BCC, basal cell carcinoma; BSC, basosquamous cell carcinoma; CR, complete response; CT, chemotherapy; NOS, not otherwise specified; PD, progressive disease; PR, partial response; RT, radiotherapy; SD, stable disease.

CASE SERIES

Considering the group of patients treated at the Dermato-Oncology Unit of Trieste, a total of 5 individuals with advanced BSC were included. The group comprised four females and one male, with a mean age of 74.6 years (range: 59–83 years) and an average follow-up time of 14.2 months (range: 3–25 months).

Four cases (Patients A-D) were characterized by laBSC, with two lesions located in the left upper limb (Patient A

and C, both with a maximum lesion diameter of 15 cm), and two in the left frontal region with orbital invasion (Patients B and D, lesions measuring 4 cm and 5 cm, respectively). These patients received sonidegib as first-line therapy, all of them resulting in an initial PR at the dosage of 200 mg/die. Patient A, experienced progressive disease (PD) 8 months after therapy initiation, leading to second-line treatment with cemiplimab, administered at 350 mg IV every 3 weeks for 6 cycles. To enhance its effectiveness, a 2-month course of radiotherapy was added, delivering 55 Gy in 22 fractions.



Last follow-up	Additional information	Adverse events (if reported)
No evidence of disease	Patient previously described by Toffoli et al. ^{2,3}	Cemiplimab: mild cutaneous rash
Patient discontinued therapy (best supportive care)	Patient previously described by Toffoli et al. ²	Sonidegib: abdominal pain (after 6 months)
Deceased (bacterial pneumonia and congestive heart failure)	Patient previously described by Toffoli et al. ^{2,3}	Sonidegib: nausea, loss of appetite, myalgia (after 3 months)
Continuing sonidegib	–	Sonidegib: muscle cramps, dysgeusia, weight loss (after 3 months)
Patient discontinued therapy after an ischemic stroke	–	–

This led to significant tumour shrinkage, enabling successful surgery and resulting in a final R0 resection of the tumour. Conversely, in Patients B, C, and D the dosing frequency of sonidegib was reduced to alternate-day administration to manage adverse events, including myalgia, muscular cramps, abdominal pain, dysgeusia, nausea, and weight loss. This dosing adjustment resulted in PD for Patient B, while Patients C and D maintained their PR.

Patient E presented with a 20 cm mBSC, located in the lumbar region and involving inguinal lymph

nodes. Vismodegib (150 mg/die) was prescribed; however, the duration of therapy was too short to observe a PR. Just 2 months after treatment initiation, the patient showed slight improvement, but vismodegib was eventually discontinued following an episode of ischemic stroke.

A comprehensive description of the 5 patients treated at the Dermato-Oncology Unit of Trieste is available as [Supplementary Material 1](#). Patients A, C, and E are represented in [Figures 1–3](#), respectively.

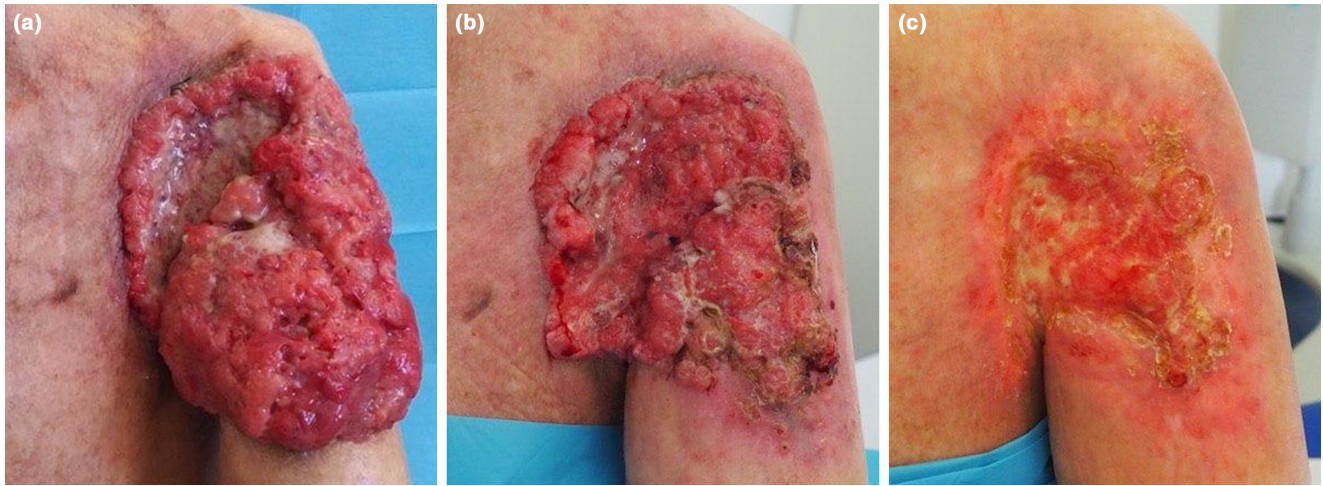


FIGURE 1 A 59-year-old woman with a locally advanced basosquamous carcinoma of the left upper limb (Patient A). (a) Baseline (July 2021); (b) After 6 months of treatment with sonidegib and 4 months of treatment with cemiplimab (July 2022); (c) After radiotherapy and re-initiation of cemiplimab (December 2022), showing excellent response.

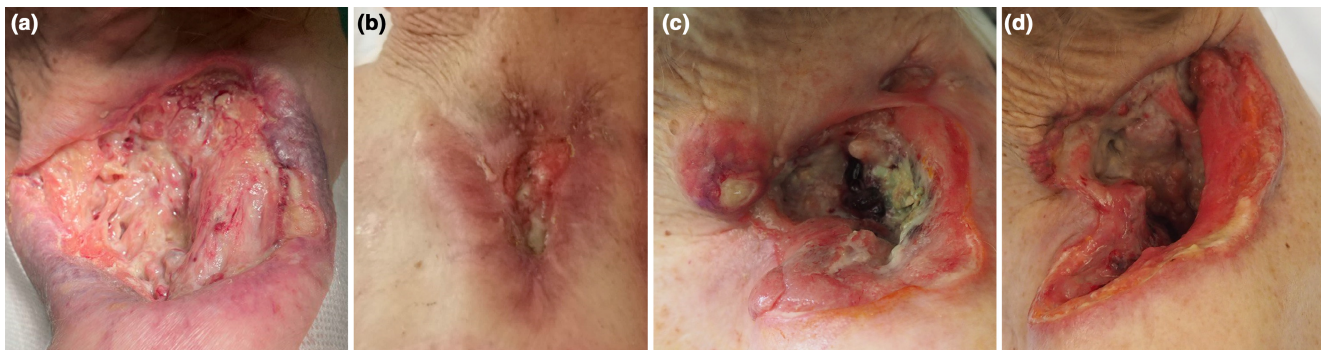


FIGURE 2 An 83-year-old woman with a locally advanced basosquamous carcinoma of the left shoulder (Patient C). (a) Baseline (May 2021); (b) After 5 months of treatment with sonidegib (October 2021), showing almost complete response; (c) After 6 months of treatment discontinuation (May 2022); (d) After 3 months of rechallenge with sonidegib (September 2022), showing initial partial response with resolution of nodular lesions.

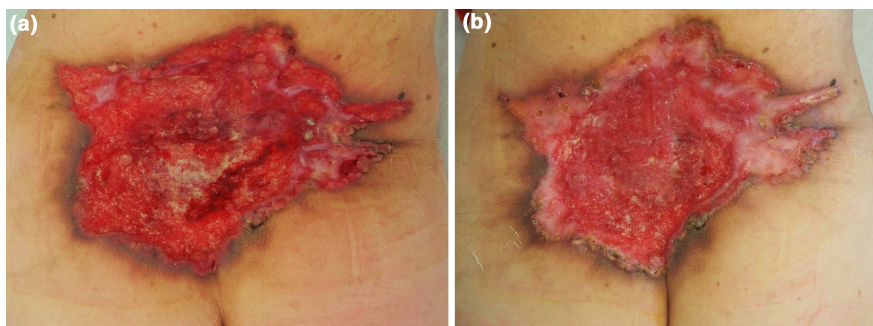


FIGURE 3 A 75-year-old woman with a locally advanced and metastatic basosquamous carcinoma of the lumbar region (Patient E). (a) Baseline (November 2022); (b) After 45 days of sonidegib (late December 2022), showing an early partial response.

FEATURES OF PATIENTS

By analysing the available literature and taking into account the 5 patients treated at the Dermato-Oncology

Unit of Trieste, a combined total of 17 cases was collected (laBSC=12, 70.6%; mBSC=5, 29.4%). This small cohort consisted of 10 women (58.8%) and 7 men (41.2%), with a mean age at diagnosis of 70.5 years (range: 45–90 years).



Most patients (13/17, 76.5%) were treated with a HHI as first line, more often vismodegib ($n=8$, including 4 mBSCs). Patients who did not receive an HHI as first line were treated with a combination of surgery and RT ($n=3$) or CT ($n=1$).

The majority of patients (10/17, 58.8%) received more than one line of therapy (6/17, 35.3%) or a combination treatment (4/17, 23.5%), usually consisting in surgery + RT (3/17, 17.6%) or surgery + HHI (1/17, 5.9%). Among the 6 patients who received more than one line of treatment, it is noticeable that all of them had a HHI as first line, while second line was cemiplimab ($n=3$), chemotherapy ($n=2$) or rechallenge with HHI after discontinuation ($n=1$). Three of these patients also were assigned to a third line of treatment, which was sonidegib + itraconazole, nivolumab or a combination of cemiplimab + RT.

In the reported cohort, no new adverse effects were identified. The most common adverse effects in patients treated with vismodegib were weight loss, dysgeusia, muscle spasms, and fatigue. On the other hand, individuals treated with sonidegib reported more often nausea, dysgeusia, loss of appetite, weight loss, abdominal pain, myalgia, muscle cramps, and alopecia. Most adverse events occurred within 3–6 months of commencing treatment. Other notable adverse events were mild anorexia and malaise (cisplatin), hepatitis and cutaneous rash (anti-PD-1 drugs).

Additional data are included in [Table 1](#).

DISCUSSION

Due to the rarity of the disease, there is currently no standard treatment for laBSC and mBSC, but there are many possible options, and each case should be managed by a multidisciplinary tailor-made approach.

Regarding the therapeutic possibilities, it is reasonable to begin treatment with a HHI such as vismodegib (the only one approved in the metastatic setting) or sonidegib. According to ERIVANCE pivotal trial, vismodegib overall response rate (ORR) at 39 months was 60.3% for laBCC and 48.5% for mBCC, with a median duration of response 26.2 and 14.8 months, respectively.²⁷ On the other hand, in the BOLT trial, sonidegib was associated with an ORR of 56% at 42 months for laBCC and a median duration of response of 26 months.²⁸ Interestingly, in the BOLT trial, aggressive histological subtypes (such as basosquamous) were also included, but the precise number of BSC cases appears to be small and it is not reported in the paper.²⁸ In a recent systematic review and meta-analysis based on 2384 patients with laBCC or mBCC, the ORR was 68.5% for vismodegib and 50.1% for sonidegib.¹ As far as concerns the specific setting of laBSC and mBSC, we do not know if these data are applicable, but in general, if

effective, HHIs are rapid and allow to obtain good results in months. Itraconazole association could be useful to improve therapy effectiveness, as suggested in the work of Ramelyte et al.⁹

The adverse events of HHIs are unpredictable and subjective, more frequently represented by weight loss, dysgeusia, alopecia, fatigue, and muscle spasms or cramps. Weight loss is more common with vismodegib, while nausea, diarrhoea, increased creatine kinase levels, and decreased appetite are more typical of sonidegib.¹ These adverse events can be managed with dose reduction (e.g., dosing on alternate days) or with drug discontinuation (temporary or definitive) because they are usually reversible. It is debated whether and when to discontinue HHI therapy, once obtained CR, but after treatment cessation, recurrence is a possible scenario, even if there are reports of a sustained response (up to 18 months).¹³

Often, after an initial response to HHI therapy, a secondary resistance can develop. In this case, the second line of treatment could be an ICI, preferably cemiplimab, since it is approved for basal cell carcinoma (after HHI failure) and there are more literature data to support this therapeutic choice. According to the phase 2 trial leading to cemiplimab approval for laBCC and mBCC, the objective response rate was 31% (6% CR and 25% PR).²¹ This was a very good result, considering that patients in this trial were by definition resistant or intolerant to HHIs, but again it remains uncertain whether this outcome is applicable to laBSC and mBSC.²¹ Radiotherapy could be associated to ICIs, in order to improve the effectiveness, since there is some evidence that RT could boost tumoral immunogenicity and treatment response, as previously reported.²⁶ Cemiplimab, as every ICI, has been associated to adverse events, in some cases severe and not reversible, therefore its role as second line can be justified. These are most commonly fatigue, diarrhoea, pruritus and cutaneous rash, anorexia, and nausea; among the immune-mediated adverse events, the most frequent is hypothyroidism, but also adrenal insufficiency, colitis, hypophysitis, immune-mediated hepatitis and kidney injury are reported.²¹

Finally, as far as concern chemotherapy, this option could be useful in some cases and according to the reports, platin-based regimens (with or without paclitaxel) are preferred.^{11,12,17}

In addition, it is necessary to underline that surgery and RT could also be combined or used in association with other therapeutic choices, in order to improve the outcome.^{16,18,19}

[Table 2](#) summarizes a treatment recommendation proposal for laBSC and mBSC (in absence of therapy contraindication), however an extensive multidisciplinary discussion of each case is always essential.

**TABLE 2** Treatment recommendation proposal of locally advanced or metastatic basosquamous carcinoma (in absence of therapy contraindication).

Line of therapy	Locally advanced BSC	Metastatic BSC
I	HHI (sonidegib/vismodegib)	HHI (vismodegib) RT and surgery as adjunctive therapy
II	Anti-PD-1 (cemiplimab)	
III	Chemotherapy (platin-based ± paclitaxel)	

Note: It is important to notice that a multidisciplinary approach with an extensive discussion of each case is required.

Abbreviations: anti-PD-1, anti-programmed death 1 receptor antibodies; BSC, basosquamous carcinoma; HHI, sonic hedgehog pathway inhibitors; RT, radiotherapy.

CONCLUSION

This work describes 5 real-life cases of advanced BSC treated at the Dermato-Oncology Unit of Trieste (Maggiore Hospital, University of Trieste). In addition, this paper provides a review of the existing treatment options for laBSC and mBSC as documented in the literature, encompassing a compilation of 17 patients in total.

In conclusion, it is necessary to underline that advanced BSCs represent a rare occurrence, but the therapeutic approach is very challenging and should be based on a multidisciplinary discussion. HHIs such as vismodegib and sonidegib could represent a safe and effective first line of treatment, while ICIs such as anti-PD-1 cemiplimab may be useful as second line. Chemotherapy and combined approaches involving surgery and radiotherapy could also be valuable in some cases.

ACKNOWLEDGEMENTS

All authors have made substantial contributions to the conception of the work, analysis and interpretation of data and have approved the final version.

FUNDING INFORMATION

None.

CONFLICT OF INTEREST STATEMENT

The authors have no conflict of interest.

DATA AVAILABILITY STATEMENT

The data underlying this paper are available in the article.

ETHICS STATEMENT

The research conforms to the ethical standards described by the Declaration of Helsinki.

INFORMED CONSENT

Informed consent has been obtained in order to publish patients' photographs and data.

ORCID

Enrico Zelin <https://orcid.org/0000-0001-9276-3627>

Vanessa Mazzoletti <https://orcid.org/0009-0000-0875-4948>

Francesco Cavallo <https://orcid.org/0000-0001-9296-826X>

Ludovica Toffoli <https://orcid.org/0000-0003-3319-6604>

Claudio Conforti <https://orcid.org/0000-0001-5126-8873>

Nicola Di Meo <https://orcid.org/0000-0002-5987-1375>

Iris Zalaudek <https://orcid.org/0000-0002-7878-4955>

REFERENCES

1. Nguyen A, Xie P, Litvinov IV, Lefrançois P. Efficacy and safety of sonic hedgehog inhibitors in basal cell carcinomas: an updated systematic review and meta-analysis (2009–2022). *Am J Clin Dermatol.* 2023;24:359–74. <https://doi.org/10.1007/s40257-023-00763-x>
2. Toffoli L, Conforti C, Zelin E, Vezzoni R, Agozzino M, di Meo N, et al. Locally advanced basal cell carcinoma: real-life data with sonidegib. *Dermatol Ther.* 2022;35:2–5. <https://doi.org/10.1111/dth.15441>
3. Toffoli L, Agozzino M, di Meo N, Zalaudek I, Conforti C. Locally advanced basosquamous carcinoma: our experience with sonidegib. *Dermatol Ther.* 2022;35:2–3. <https://doi.org/10.1111/dth.15436>
4. Mohan SV, Chang J, Li S, Henry AS, Wood DJ, Chang ALS. Increased risk of cutaneous squamous cell carcinoma after Vismodegib therapy for basal cell carcinoma. *JAMA Dermatol.* 2016;152:527–32. <https://doi.org/10.1001/jamadermatol.2015.4330>
5. Iarrobino A, Messina JL, Kudchadkar R, Sondak VK. Emergence of a squamous cell carcinoma phenotype following treatment of metastatic basal cell carcinoma with vismodegib. *J Am Acad Dermatol.* 2013;69:e33–4. <https://doi.org/10.1016/j.jaad.2013.01.023>
6. Bancalari B, Llombart B, Serra-Guillén C, Bernia E, Requena C, Nagore E, et al. Histologic changes during treatment with Vismodegib in locally advanced basal cell carcinoma: a series of 19 cases. *Am J Dermatopathol.* 2019;41:711–7. <https://doi.org/10.1097/DAD.0000000000001384>
7. Bhutani T, Abrouk M, Sima CS, Sadetsky N, Hou J, Caro I, et al. Risk of cutaneous squamous cell carcinoma after treatment of basal cell carcinoma with vismodegib. *J Am Acad Dermatol.* 2017;77:713–8. <https://doi.org/10.1016/j.jaad.2017.03.038>
8. Apalla Z, Papageorgiou C, Lallas A, Sotiriou E, Lazaridou E, Vakirlis E, et al. Spotlight on vismodegib in the treatment of



- basal cell carcinoma: an evidence-based review of its place in therapy. *Clin Cosmet Investig Dermatol*. 2017;10:171–7. <https://doi.org/10.2147/CCID.S101330>
9. Ramelyte E, Restivo G, Imhof L, Nägeli MC, Dummer R. How to break resistance to hedgehog inhibitors in advanced basal cell carcinoma? *Br J Dermatol*. 2021;184:359–61. <https://doi.org/10.1111/bjd.19501>
 10. Gambichler T, Stricker I, Neid M, Tannapfel A, Susok L. Impressive response to four cemiplimab cycles of a sonidegib-resistant giant basosquamous carcinoma of the midface. *J Eur Acad Dermatol Venereol*. 2022;36:e492. <https://doi.org/10.1111/jdv.17993>
 11. Papageorgiou C, Apalla Z, Timotheadou E, Loga K, Lazaridou E, Dionysopoulos D. A case of metastatic basal cell carcinoma treated with carboplatin and paclitaxel. *Dermatol Pract Concept*. 2023;13:e2023002. <https://doi.org/10.5826/dpc.1301a2>
 12. Sheen Y-T, Sheen M-C, Sheu H, Sheen Y. Intra-arterial infusion chemotherapy in the treatment of advanced basosquamous carcinoma of the nose. *JAAD Case Rep*. 2021;14:97–100. <https://doi.org/10.1016/j.jcdr.2021.06.018>
 13. Apalla Z, Giakouvis V, Gavros Z, Lazaridou E, Sotiriou E, Bobos M, et al. Complete response of locally advanced basosquamous carcinoma to vismodegib in two patients. *Eur J Dermatol*. 2019;29:102–4. <https://doi.org/10.1684/ejd.2018.3482>
 14. Sahuquillo-Torralla A, Llavador-Ros M, Caballero-Daroqui J, Botella-Estrada R. Complete response of a locally advanced basosquamous carcinoma with vismodegib treatment. *Indian J Dermatol Venereol Leprol*. 2019;85:549–52. https://doi.org/10.4103/ijdv.IJDVL_647_18
 15. McGrane J, Carswell S, Talbot T. Metastatic spinal cord compression from basal cell carcinoma of the skin treated with surgical decompression and vismodegib: case report and review of hedgehog signalling pathway inhibition in advanced basal cell carcinoma. *Clin Exp Dermatol*. 2017;42:80–3. <https://doi.org/10.1111/ced.12991>
 16. Bisgaard E, Tarakji M, Lau F, Riker A. Neglected skin cancer in the elderly: a case of basosquamous cell carcinoma of the right shoulder. *J Surg Case Rep*. 2016;8:1–3. <https://doi.org/10.1093/jscr/rjw134>
 17. Borradori L, Sutton B, Shayesteh P, Daniels GA. Rescue therapy with anti-programmed cell death protein 1 inhibitors of advanced cutaneous squamous cell carcinoma and basosquamous carcinoma: preliminary experience in five cases. *Br J Dermatol*. 2016;175:1382–6. <https://doi.org/10.1111/bjd.14642>
 18. Al-Wassia RK. Intensity modulated radiotherapy is an effective treatment for basosquamous cell cancer. *J King Abdulaziz Univ - Med Sci*. 2015;22:53–8. <https://doi.org/10.4197/Med.22-1.8>
 19. Deganello A, Gitti G, Struijs B, Paiar F, Gallo O. Palliative combined treatment for unresectable cutaneous basosquamous cell carcinoma of the head and neck. *Acta Otorhinolaryngol Ital*. 2013;33:353–6.
 20. Shiravand Y, Khodadadi F, Kashani SMA, Hosseini-Fard SR, Hosseini S, Sadeghirad H, et al. Immune checkpoint inhibitors in cancer therapy. *Curr Oncol*. 2022;29:3044–60. <https://doi.org/10.3390/curroncol29050247>
 21. Stratigos AJ, Sekulic A, Peris K, Bechter O, Prey S, Kaatz M, et al. Cemiplimab in locally advanced basal cell carcinoma after hedgehog inhibitor therapy: an open-label, multi-centre, single-arm, phase 2 trial. *Lancet Oncol*. 2021;22:848–57. [https://doi.org/10.1016/S1470-2045\(21\)00126-1](https://doi.org/10.1016/S1470-2045(21)00126-1)
 22. Véron M, Chevret S, Grob J-J, Beylot-Barry M, Saiag P, Fléchon A, et al. Safety and efficacy of nivolumab, an anti-PD1 immunotherapy, in patients with advanced basal cell carcinoma, after failure or intolerance to sonic hedgehog inhibitors: UNICANCER AcSé NIVOLUMAB trial. *Eur J Cancer*. 2022;177:103–11. <https://doi.org/10.1016/j.ejca.2022.09.013>
 23. Munhoz RR, Nader-Marta G, de Camargo VP, Queiroz MM, Cury-Martins J, Ricci H, et al. A phase 2 study of first-line nivolumab in patients with locally advanced or metastatic cutaneous squamous-cell carcinoma. *Cancer*. 2022;128:4223–31. <https://doi.org/10.1002/cncr.34463>
 24. Stratigos A, Sekulic A, Peris K, Bechter O, Kaatz M, Lewis K, et al. Primary analysis of phase 2 results for Cemiplimab in patients (pts) with locally advanced basal cell carcinoma (laBCC) who Progress on or are intolerant to hedgehog inhibitors (HHIs). *Ski J Cutan Med*. 2021;5:s4. <https://doi.org/10.25251/skin.5.supp.4>
 25. Fotiadou C, Apalla Z, Lazaridou E. Basosquamous carcinoma: a commentary. *Cancers (Basel)*. 2021;13:6146. <https://doi.org/10.3390/cancers13236146>
 26. Keam S, Gill S, Ebert MA, Nowak AK, Cook AM. Enhancing the efficacy of immunotherapy using radiotherapy. *Clin Transl Immunol*. 2020;9:e1169:1–20. <https://doi.org/10.1002/cti2.1169>
 27. Sekulic A, Migden MR, Basset-Seguín N, Garbe C, Gesierich A, Lao CD, et al. Long-term safety and efficacy of vismodegib in patients with advanced basal cell carcinoma: final update of the pivotal ERIVANCE BCC study. *BMC Cancer*. 2017;17:332. <https://doi.org/10.1186/s12885-017-3286-5>
 28. Dummer R, Guminksi A, Gutzmer R, Lear JT, Lewis KD, Chang ALS, et al. Long-term efficacy and safety of sonidegib in patients with advanced basal cell carcinoma: 42-month analysis of the phase II randomized, double-blind BOLT study. *Br J Dermatol*. 2020;182:1369–78. <https://doi.org/10.1111/bjd.18552>

SUPPORTING INFORMATION

Additional supporting information can be found online in the Supporting Information section at the end of this article.

How to cite this article: Zelin E, Mazzoletti V, Cavallo F, Nardello C, Corio A, Toffoli L, et al. Treatment of locally advanced and metastatic basosquamous carcinoma, navigating among sonic hedgehog pathway inhibitors, immune checkpoint inhibitors, chemotherapy, and radiotherapy: A case series and literature review. *Australas J Dermatol*. 2024;65:103–113. <https://doi.org/10.1111/ajd.14182>